# Neuroanatomy and Neuroembryology

I. Terminology

A. Anatomical references

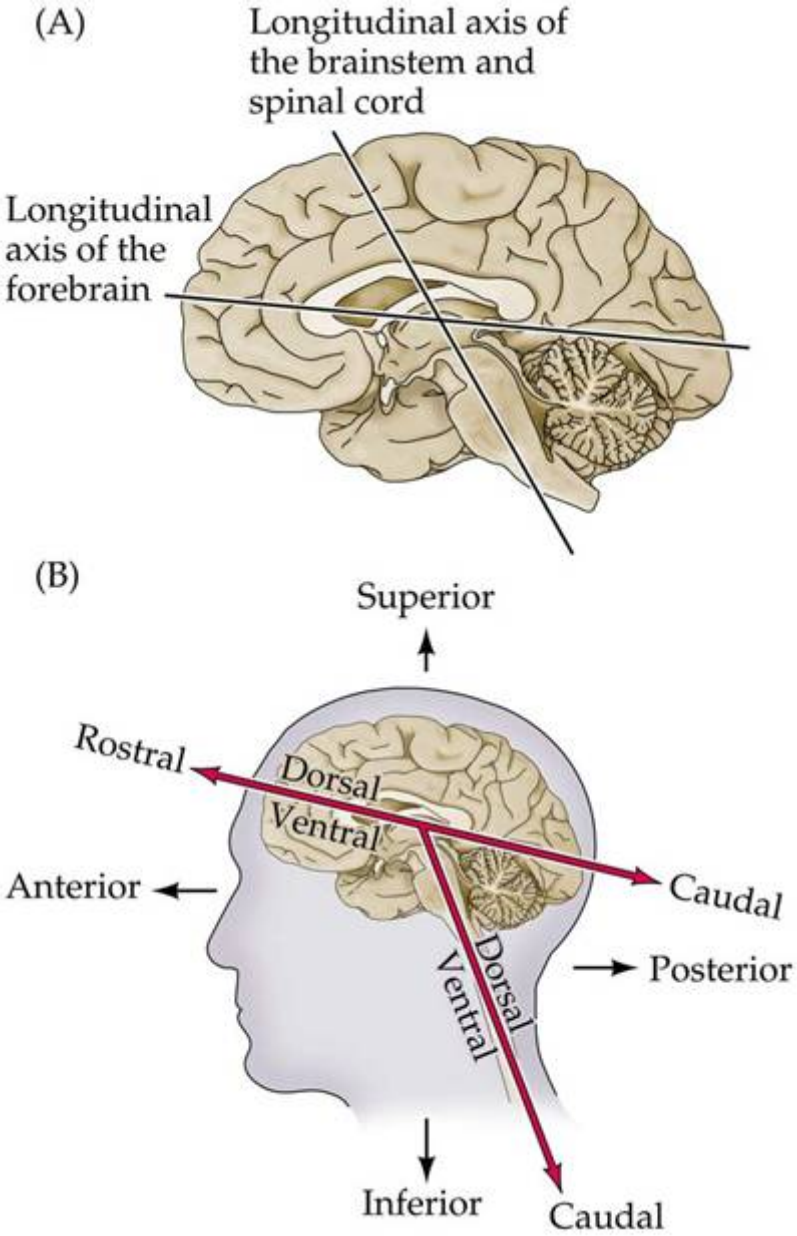


1. Anatomical structures can be divided into front and back
    - a. Front
        - i. Anterior
        - ii. Rostral
    - b. Back
        - i. Posterior
        - ii. Caudal
2. Anatomical structures can be divided into top and bottom
    - a. Superior
        - i. Dorsal (Posterior for bipeds)
    - b. Inferior
        - i. Ventral (Anterior for bipeds)
3. Anatomical structures can be divided into sides
    - a. Midline
    - b. Medial
        - i. Close to the midline

c. Lateral
i. Away from the midline

4. Relative position of anatomical structures
a. Ipsilateral
i. Structures localized to the same side
b. Contralateral
i. Structures localized to different sides
c. Proximal
i. Close to a fixed reference point
d. Distal
i. Distant to a fixed reference point

5. Anatomical structures can be sectioned along flat surfaces (planes)

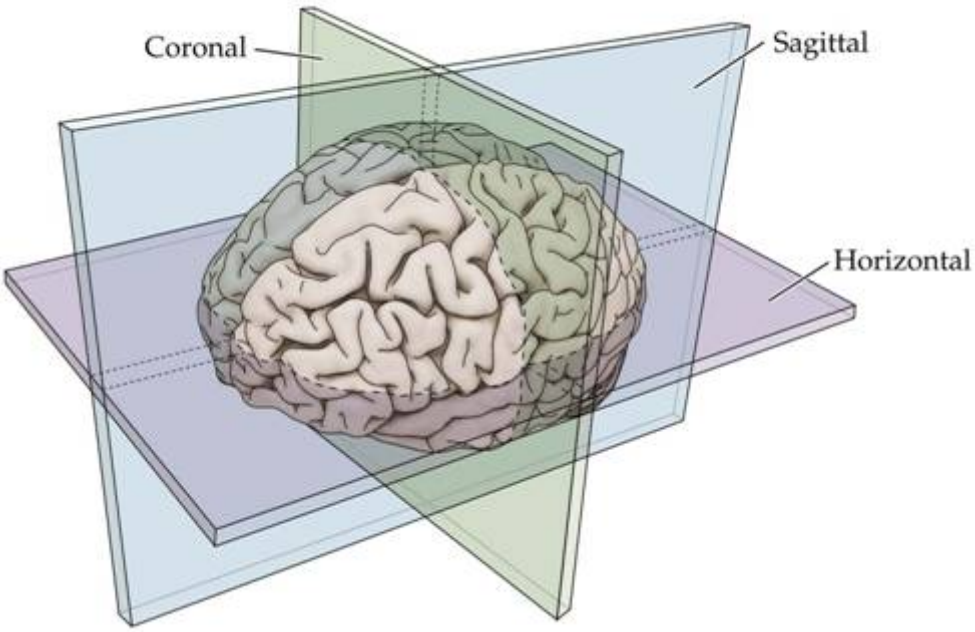


a. Coronal (frontal)
i. Vertical plane dividing structure into anterior/posterior parts
b. Sagittal
i. Vertical plane dividing structure into right and left halves
ii. Midsaggital (median)
iii. Parasagittal
c. Horizontal (transverse)
i. Divides structure into superior and inferior

6. Longitudinal axis
a. Nervous system is organized along an anterior to posterior axis
b. Different regions of the brain have different longitudinal axis
i. Cerebellum is ventral to the forebrain axis but dorsal to that of the brain stem

Note: The nervous system is organized along an anterior to posterior axis with a fluid filled tube running through the center. At the anterior end, the structure have enlarged with evolutionary advancement and to accommodate for this enlargement, the brain has become distorted and curved so that some structures are more difficult to assign anatomical references.

B. Nervous system terminology

1. Neural cell bodies are often organized in rows
a. Lamina
i. Row or layer of cell bodies separated from another row or layer by a layer of axons or dendrites

        ii. Parallel to structural surface
    b. Column
        i. Row of cells perpendicular to the surface of the brain
        ii. Share a common function
2. Terms referring to neuron cell bodies found in CNS
    a. Grey matter
        i. Generic term for neurons in the CNS
    b. Nucleus
        i. Clearly defined mass of neuron cell bodies
    c. Substantia
        i. Less distinct borders than nuclei
    d. Locus
        i. Small but well defined mass of neuron cell bodies
3. Terms referring to neuron cell bodies found in PNS
    a. Ganglion
        i. Collection of neurons in the PNS
4. Terms referring to axons
    a. White matter
        i. Generic term for a collection of axons
    b. Tract (projection)
        i. Refers to CNS
        ii. Set of axons, also known as fibers, that project from one structure and form synapses on a second common structure
    c. Nerve
        i. Refers to PNS
        ii. Bundle of axons either projecting from the CNS to a muscle or gland or from a sense organ to the CNS
    d. Bundle
        i. Collection of axons that run together but do not necessarily share the same origin or destination
    e. Commissure
        i. Any collection of axons that connect one side of the brain with the other side
5. Terms that refer to the external morphology of the brain
    a. Surface convolutions
        i. Gyrus: ridge on the surface of the cerebrum (and cerebellum)
        ii. Sulcus: groove
        iii. Fissure: a deep groove
6. Important sulci and gyri

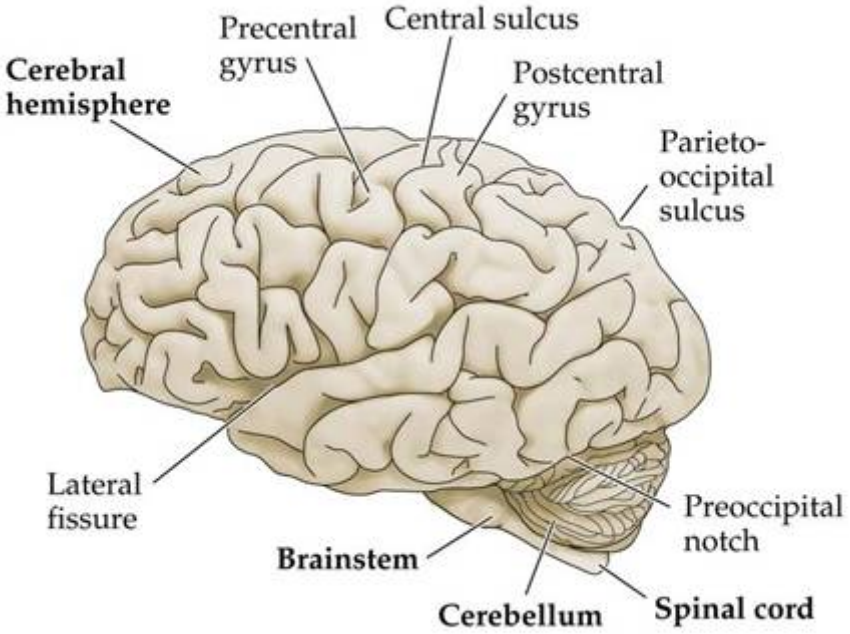


a. Central sulcus
    i. Separates frontal (anterior) and parietal lobes (posterior)
b. Precentral gyrus
    i. Commonly known as the motor cortex
c. Postcentral gyrus
    i. Somatosensory cortex
d. Sylvian (lateral) fissure
    i. Separates temporal and frontal lobes
    ii. Temporal is inferior to the frontal and extends to the caudally located occipital lobe
    iii. Parietal lobe is superior to lateral fissure
e. Insula
    i. Fold created by the temporal lobe
    ii. Commonly referred to as the operculum
f. Parieto-occipital sulcus
    i. Extends from superior to inferior surface
    ii. Divides parietal from occipital lobes
g. Calcarine sulcus
    i. Medial surface of the occipital lobe
    ii. Defines the location of the visual cortex
h. Cingulate sulcus
    i. Medial surface of the frontal and parietal lobes
    ii. Inferior to this sulcus is the limbic lobe

C. Organization of the nervous system
1. Functionally organized into two divisions
    a. Central nervous system (CNS)
        i. Brain (Cerebellum, cerebrum and brain stem)
        ii. Spinal cord
    b. Peripheral nervous system (PNS)
        i. Somatic
        ii. Autonomic
2. Organization of gray and white matter
    a. CNS
        i. Gray matter is organized on the surface of the brain in lamina

ii. White matter is organized centrally
iii. White matter constitutes the majority of brain mass

b. PNS
i. Gray matter is centrally located
ii. White matter is organized on the surface

II. Cerebral Hemispheres
A. General characteristic of the cerebral hemispheres
1. Organized into functional areas
a. Motor
i. Voluntary control of movement
b. Sensory
i. Conscious awareness of sensation
c. Association
i. Integration
ii. Emergent properties
2. Contralateral control of the body
a. Each hemisphere is concerned with the opposite of the body
3. Functions are lateralized
a. Each hemisphere has unique functions
4. Function arises from concerted activity
5. Lobes

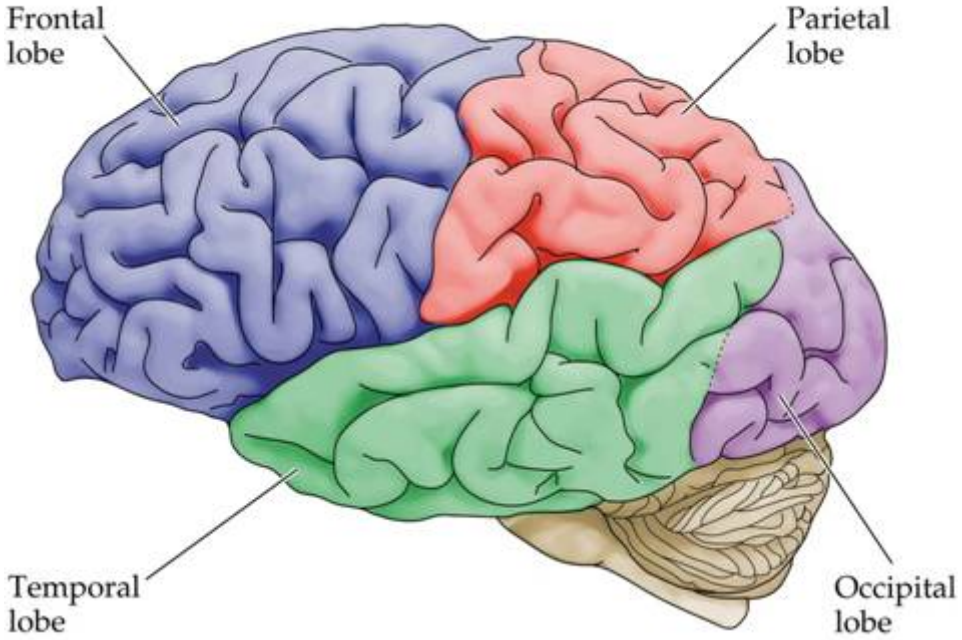


a. Frontal
b. Parietal
c. Temporal
d. Occipital
B. Motor areas
1. Cortical areas involved in movement
a. Primary motor cortex
b. Premotor cortex
c. Broca's area
d. Frontal eye field
2. Primary motor cortex (Brodmann 4)
a. Located in the precentral gyrus of frontal lobe

b. Conscious control of motor execution
c. Pyramidal cells give rise to the corticospinal tracts
d. Somatotopy
i. Body is mapped (motor homunculus)
ii. Representation is proportionate to level of motor control
iii. Innervation is primarily contralateral

3. Premotor cortex (Brodmann 6)
a. Learned motor skills
i. Patterned or repetitious

4. Broca's area (Brodmann 44/45)
a. Directs muscles of the tongue, throat and lips
b. Motor planning for speech related activity

5. Frontal eye field (Brodmann 8)
a. Voluntary movement of the eyes

C. Sensory areas

1. Cortical areas involved in processing sensation
a. Primary somatosensory cortex
b. Somatosensory association area
c. Visual cortex
d. Auditory cortex
e. Olfactory cortex
f. Gustatory cortex

2. Primary somatosensory cortex (Brodmann 1, 2 & 3)
a. Parietal lobe
i. Postcentral gyrus
b. Somatic senses
i. Pain and temperature
ii. Touch and proprioception
c. Somatotopy

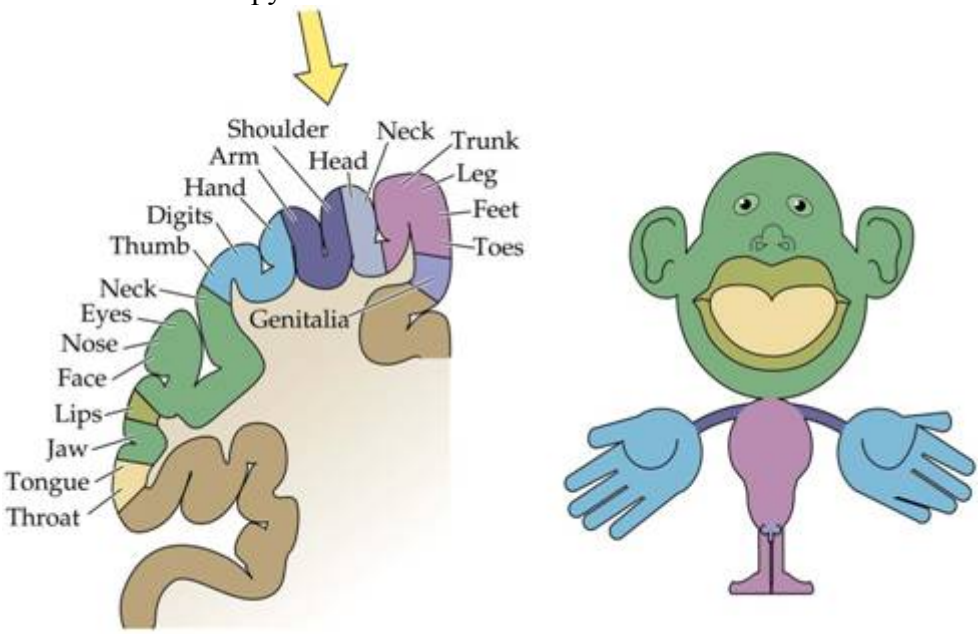


i. Body is mapped (somatosensory homunculus)
ii. Representation is proportionate to number of sensory receptors
iii. Innervation is primarily contralateral

3. Somatosensory association area (Brodmann 5 & 7)
a. Integrate various somatic sensory inputs

4. Visual areas
a. Primary visual cortex (Brodmann 17)

i. Occipital lobe
ii. Located primarily in the calcarine sulcus
iii. Sensory function with largest cortical representation
iv. Innervation is primarily contralateral
b. Visual association areas (Brodmann 18 & 19)
i. Interpretation of visual stimuli
ii. Past visual experiences
5. Auditory areas
a. Primary auditory cortices (Brodmann 41)
i. Superior margin of temporal lobe
ii. Pitch, rhythm and loudness
b. Auditory association area (Brodmann 42 & 43)
i. Recognition of stimuli as specific auditory experiences (e.g., speech)
6. Olfactory cortex
a. Medial aspects of temporal lobe
i. Piriform lobe (uncus)
7. Gustatory cortex (Brodmann 43)
a. Parietal lobe deep to the temporal lobe

D. Association areas
1. Characteristics
a. Analyze, recognize and act on sensory in puts
b. Multiple inputs and outputs
2. Association areas (in addition to those discussed above)
a. Prefrontal cortex
b. Gnostic area
c. Language areas
3. Prefrontal cortex (Brodmann 11 & 47)
a. Anterior portion of frontal lobe
b. Intelligence, complex learned behavior and personality
c. Understanding written and spoke language
4. General interpretation area
a. Encompasses parts of temporal, parietal and occipital lobes
i. Generally found on the left side
b. Storage of complex sensory memories
5. Language areas
a. Bilaterally located
b. Wernicke's area
i. Posterior temporal lobe on left side
ii. Sounding out unfamiliar words
c. Affective language areas
i. Located contralateral to Broca's and Wernicke's areas
ii. Nonverbal and emotional components of language
E. Organization of the cortex
1. Common features
a. Cell bodies are arranged in sheets (layers)
i. Parallel to surface of brain
b. Layer I lacks cell bodies
i. Molecular layer
c. At least one layer has pyramidal cells
i. Emit large apical dendrites
ii. Extend up to layer I
2. Cytoarchitecture
a. Lamina

i. Layers of cells parallel to brain surface

b. Columns

i. Row of cells perpendicular to brain surface

ii. Share a common function

3. Neocortical layers

a. Layer I

i. Few cells; primarily axons, dendrites and synapses

b. Layers II & III

i. Pyramidal cells that project to and receive projections from other cortical regions

c. Layer IV

i. Stellate cells that receive most of thalamic input and project locally to other lamina

d. Layer V & VI

i. Pyramidal neurons that project to subcortical regions such as the thalamus, brainstem, and spinal cord, and other cortical areas

III. Subcortical Structures

A. Basal nuclei (ganglia)

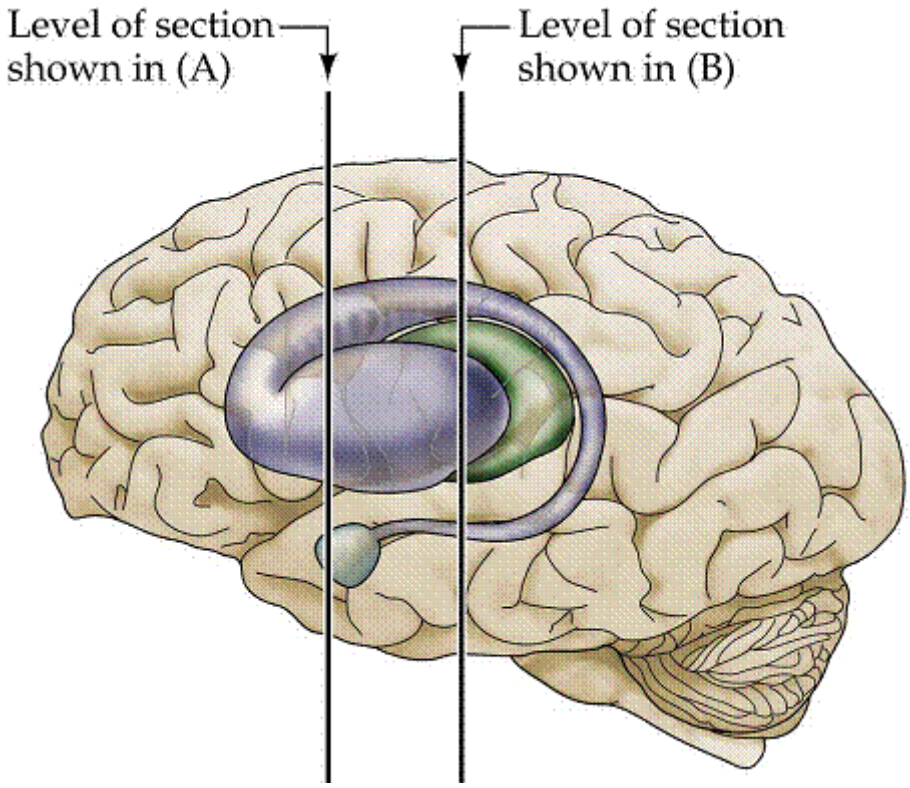

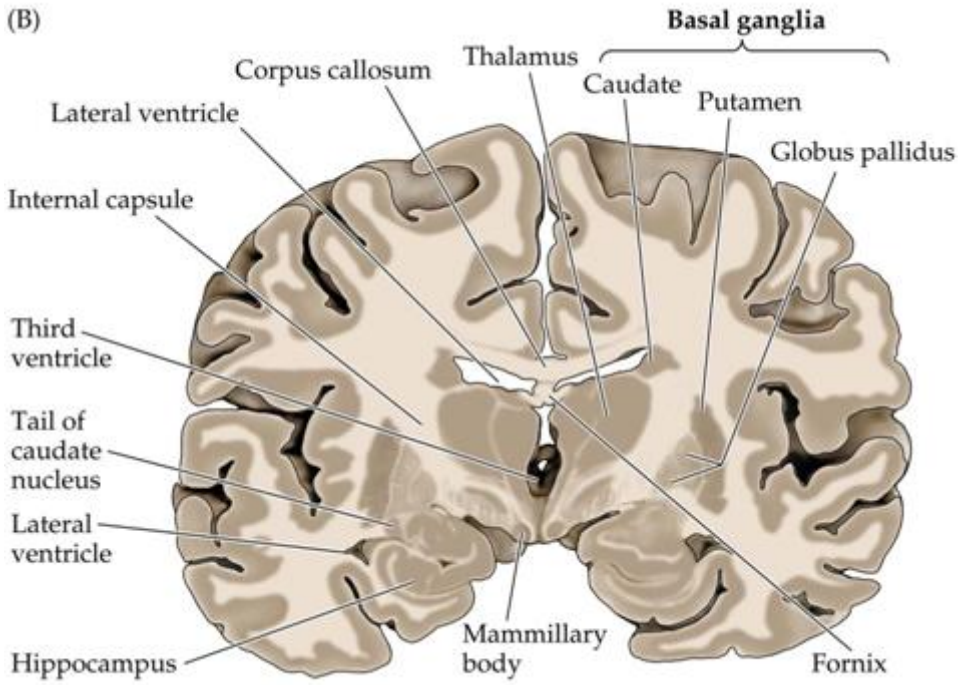


1. Structures
    a. Caudate
    b. Putamen
    c. Globus pallidus
2. Organization
    a. Receive inputs from most cortical structures
    b. Project to motor cortex via the thalamus
3. Function
    a. Motor control
        i. Starting, stopping and monitoring movement
        ii. Inhibit unnecessary movement

B. Diencephalon

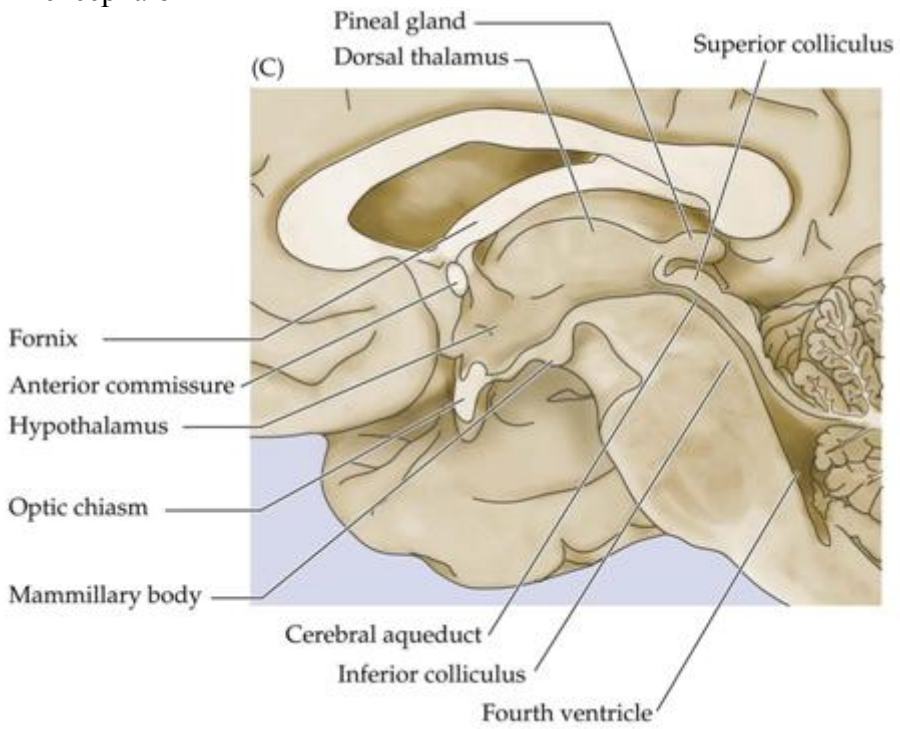


1. Organization

a. Core of forebrain
    i. Surrounded by cerebral hemispheres
b. Three bilateral structures
    i. Thalamus
    ii. Hypothalamus
    iii. Epithalamus

2. Thalamus
    a. Comprised of multiple nuclei
        i. Each nucleus receives specific afferent projections
        ii. Nuclei interconnect
        iii. Nuclei project (relay) processed information to particular cortical areas
    b. Process and relay information
3. Hypothalamus
    a. Location
        i. Between optic chiasm and mammillary bodies
        ii. Below thalamus
    b. Connected to the pituitary
        i. Via infundibulum
    c. Visceral control center of the body
        i. Autonomic control (e.g., BP, HR)
        ii. Emotional response (e.g., fear, sex drive)
        iii. Regulation of body temperature
        iv. Regulation of feeding
        v. Regulation of thirst
        vi. Regulation of circadian rhythm
        vii. Control of endocrine function
4. Epithalamus
    a. Pineal body
        i. Control of sleep-cycle
        ii. Melatonin
    b. Choroid plexus
        i. Production of cerebral spinal fluid (CSF)

IV. Brain Stem

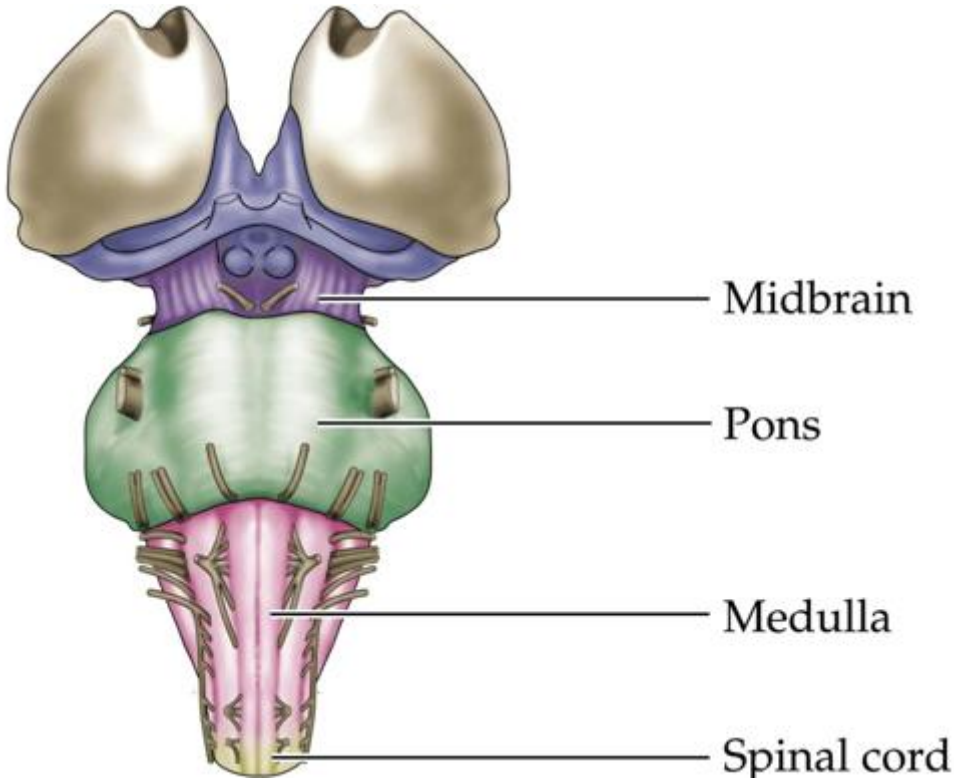


A. Organization
1. Functional areas
    a. Midbrain
    b. Pons
    c. Medulla oblongata
B. Functions
1. Autonomic behavior
2. Pathway for fiber tracts
3. Cranial nerves
C. Midbrain
1. Structures
    a. Cerebral peduncles
        i. Fiber tracts connecting cerebrum with inferior structures
    b. Corpora quadrigemina
        i. Superior and inferior colliculi
    c. Substantia nigra
        i. Color is due to melanin (DA precursor)
        ii. Nucleus of DA neurons
    d. Red nucleus
        i. Motor reflex
    e. Reticular formation
        i. Some of the RF nuclei are found here (see below)
D. Pons
1. Lies between midbrain and medulla
2. Comprised mostly of conducting fibers
    a. Connection between higher brain areas and spinal cord
        i. Longitudinal projections
    b. Pontine nuclei
        i. Relay information between motor cortex and cerebellum
3. Nuclei for several cranial nerves
    a. Trigeminal (V)
    b. Abducens (VI)

c. Facial (VII)

E. Medulla oblongata

1. Lies between pons and spinal cord
    a. No obvious demarcation between medulla and spinal cord
2. Landmarks
    a. Pyramids
        i. Descending corticospinal tracts
        ii. Decussate
3. Nuclei for several cranial nerves
    a. Hypoglossal (XII)
    b. Glossopharyngeal (IX)
    c. Vagus (X)
    d. Accessory (XI)
    e. Vestibulocochlear (VIII)
4. Control of visceral motor function
    a. Cardiovascular center
        i. Cardiac center
        ii. Vasomotor center
    b. Respiratory center
        i. Control rate and depth of breathing
    c. Reflex
        i. Vomit
        ii. Hiccup
        iii. Swallowing
        iv. Coughing
        v. Sneezing

V. Cerebellum

A. Anatomy

1. Location
    a. Dorsal to pons and medulla
    b. Caudal to occipital lobe
2. Structure
    a. Bilateral
    b. Consists of cerebellar hemispheres
        i. Connected by vermis
    c. Hemispheres consists of lobes
        i. Posterior
        ii. Anterior
        iii. Flocolonodular
    d. Gray and white matter is organized like cerebrum
        i. Gray outside/white inside
    e. Cerebellum is connected via cerebellar peduncles
        i. Fiber tracts connecting brain stem and sensory cortices with cerebellum

B. Function

1. Precise timing of skeletal contraction
    a. Sensory and motor information is integrated

VI. Brain Systems

A. Limbic system

1. Group of cortical structures
    a. Located on medial aspect of the cerebral hemisphere and diencephalon
    b. Connectivity is complex
2. Structures
    a. Upper part of brainstem

b. Rhinencephalon
i. Septal nuclei
ii. Cingulate gyrus
iii. Parahippocampal gyrus
iv. Hippocampus
c. Amygdala
d. Diencephalon structures
i. Hypothalamus
ii. Anterior nucleus of the thalamus
e. Fiber tracts
i. Fornix
ii. Fimbria
3. Function
a. Emotional and affective state
B. Reticular formation
1. Complex of nuclei and white matter
a. Disperse and widespread connectivity
2. Location
a. Central core of medulla, pons and midbrain
3. Function
a. Maintain wakefulness and attention
i. Coordination of all afferent sensory information
b. Coordination of muscle activity
i. Modulation of efferent motor information

VII. Protection of the Brain
A. Primary mechanism
1. Bone
a. Brain is encased in a bony skullcap
2. Membranes
a. Meninges
3. Fluid
a. Cerebrospinal fluid
b. Blood-brain barrier
B. Meninges

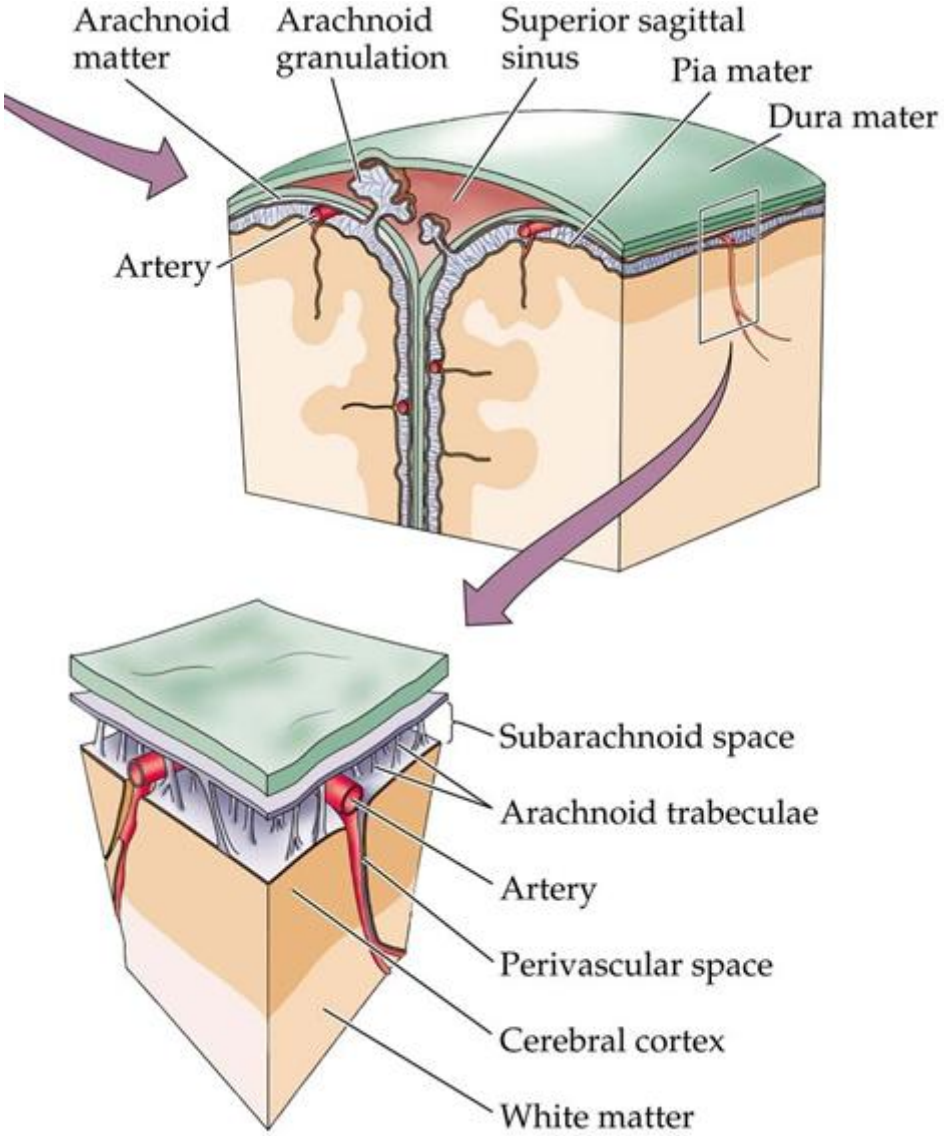


1. Structure
    a. Three connective tissue membranes
        i. Dura mater (tough mother)
        ii. Arachnoid mater (spider mother)
        iii. Pia mater (gentle mother)
2. Dura
    a. Two fused layers
        i. Periosteal layer
        ii. Meningeal layer
    b. Periosteal layer is attached to the skull
        i. Spinal cord does not have a periosteal layer
    c. Meningeal layer covers brain and spinal cord
    d. Dura projects inward to help anchor the brain
    e. Dural septa
        i. Falx cerebri
        ii. Falx cerebelli
        iii. Tentorium
    f. Dural sinuses
        i. Spaces between dural layers
        ii. Collect venous blood flow from brain
        iii. Directs blood flow back to jugular veins
3. Arachnoid

a. Loose cover over brain
    i. Does not enter sulci
b. Small space between dura and arachnoid
    i. Subdural space
c. Subarchnoid space
    i. Deep to arachnoid
    ii. Filled with CSF
    iii. Secured to pia by weblike extensions of the arachnoid
d. Arachnoid villi
    a. Act like valves
    b. Projection of archoid through dura into dural sinuses
    c. Permits CSF to be absorbed into venous blood

4. Pia
    a. Clings tightly to brain
    b. Invested with blood vessels

C. Cerebrospinal fluid (CSF)

1. Function
    a. Form a liquid cushion for CNS organs
    b. Provides nutrients
    c. CSF composition is monitored
        i. Control of autonomic functions
2. Found in ventricles (see below) and central canal of spinal cord
3. Choroid plexuses
    a. Produce CSF
    b. Located in ventricles
4. Flow
    a. Produced in ventricles
    b. Exit 4th ventricle
    c. Bath brain
    d. Absorbed into venous blood through arachnoid villi
5. Anatomy of the ventricular system

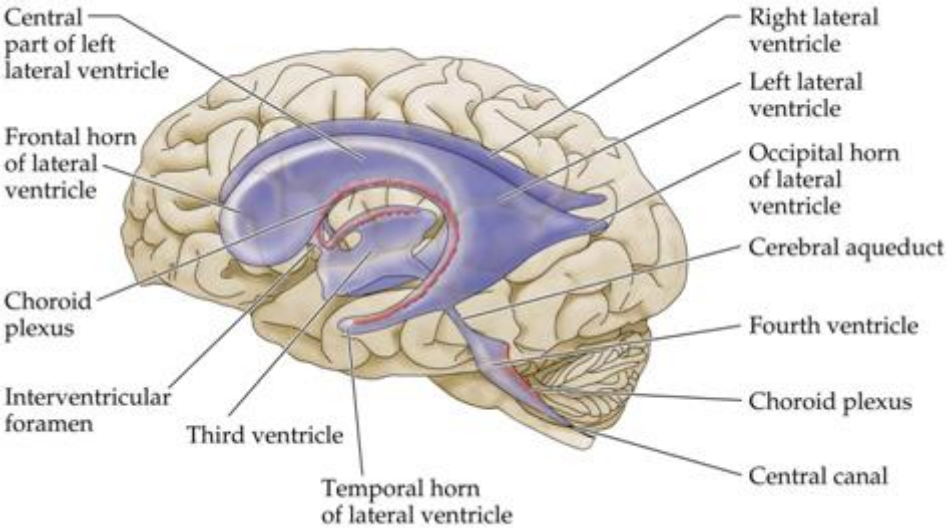


a. Four fluid-filled chambers
    i. Paired lateral
    ii. Third
    iii. Fourth
b. Chambers are continuous with each other and with the central canal of the spinal cord

c. Interventricular foramen connect lateral with third
d. Third is connected with fourth via cerebral aqueduct
e. Fourth is continuous with central canal
f. Fourth has openings to subarachnoid space
i. Lateral apertures
ii. Median aperture

D. Blood-brain barrier

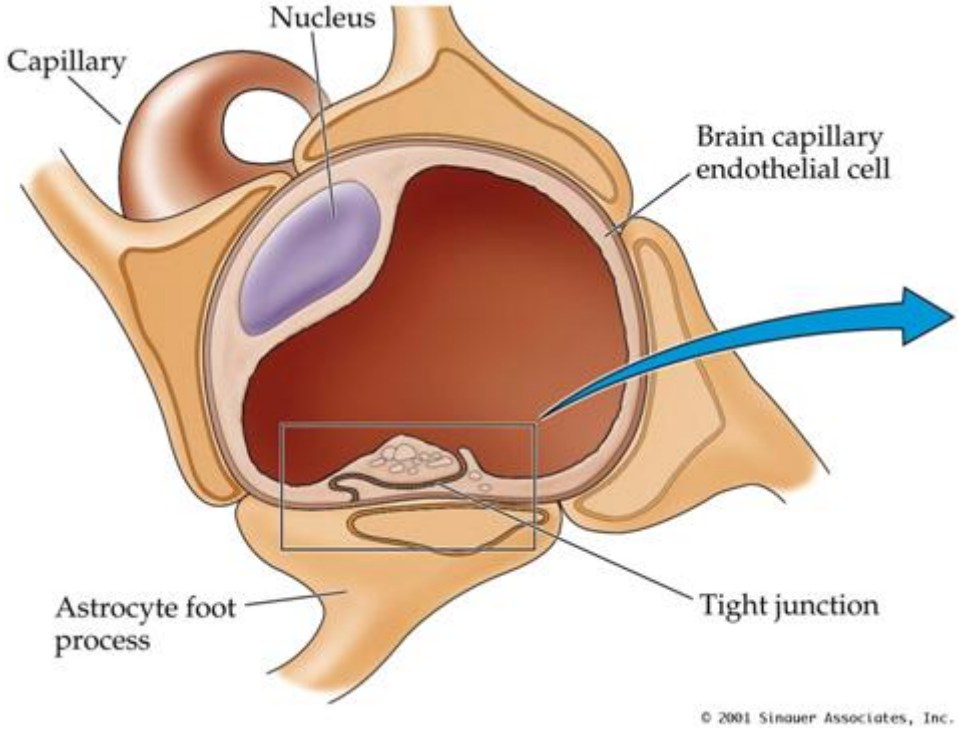


1. Brain environment is tightly controlled
a. Most bloodborne substances cannot readily enter the brain
2. Mechanism
a. Capillary endothelium is joined by tight junctions
i. Relatively impermeable
3. Barrier is selective
a. Facilitated diffusion of particular substances
i. Glucose and others
b. Cannot prevent fat-soluble molecules from diffuses into brain

VIII. Spinal Cord
A. Gross anatomy

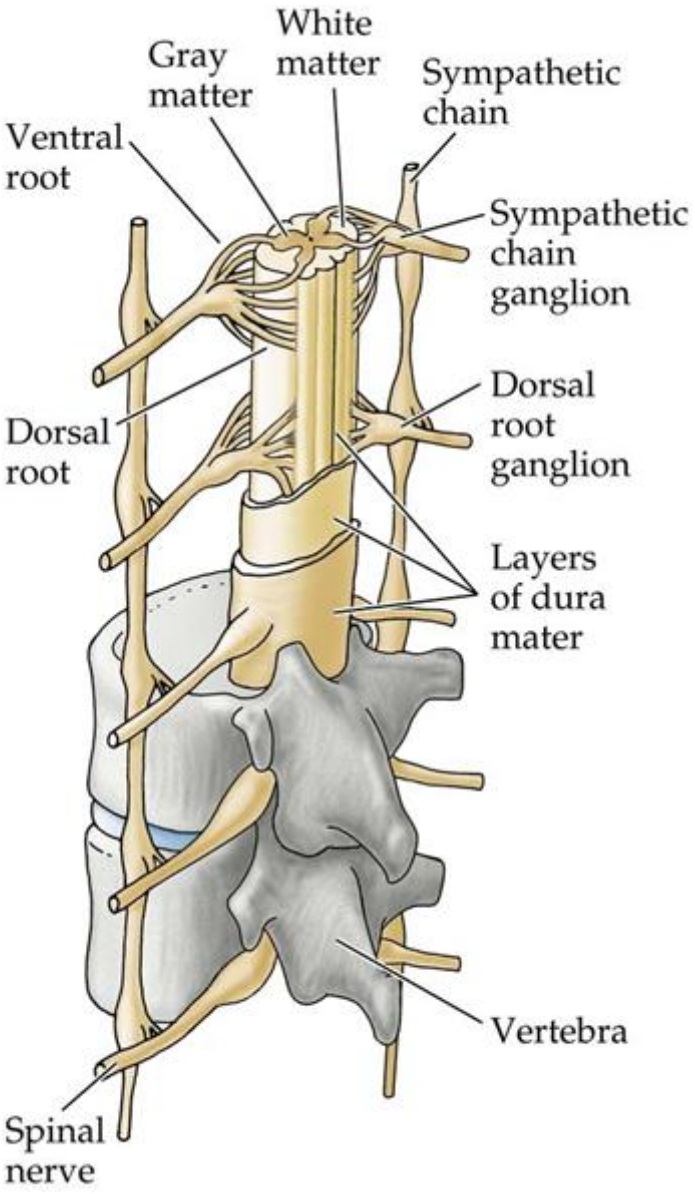


1. Protected
    a. Bone
        i. Vertebral column
    b. Membranes
        i. Meninges
    c. Fluid
        i. CSF
2. Meninges
    a. Single layer
        i. Spinal dural sheath
    b. Epidural space
        i. Padding of fat between vertebrae and dural sheath
    c. Subarachnoid space
        i. Filled with CSF
    d. Extend to $S_2$
        i. Spinal cord only extends to $L_1$
3. Attachments
    a. Denticulate ligaments
        i. Attached to vertebrae laterally

b. Filum terminale
i. Attached to coccyx caudally

B. Cross-sectional anatomy

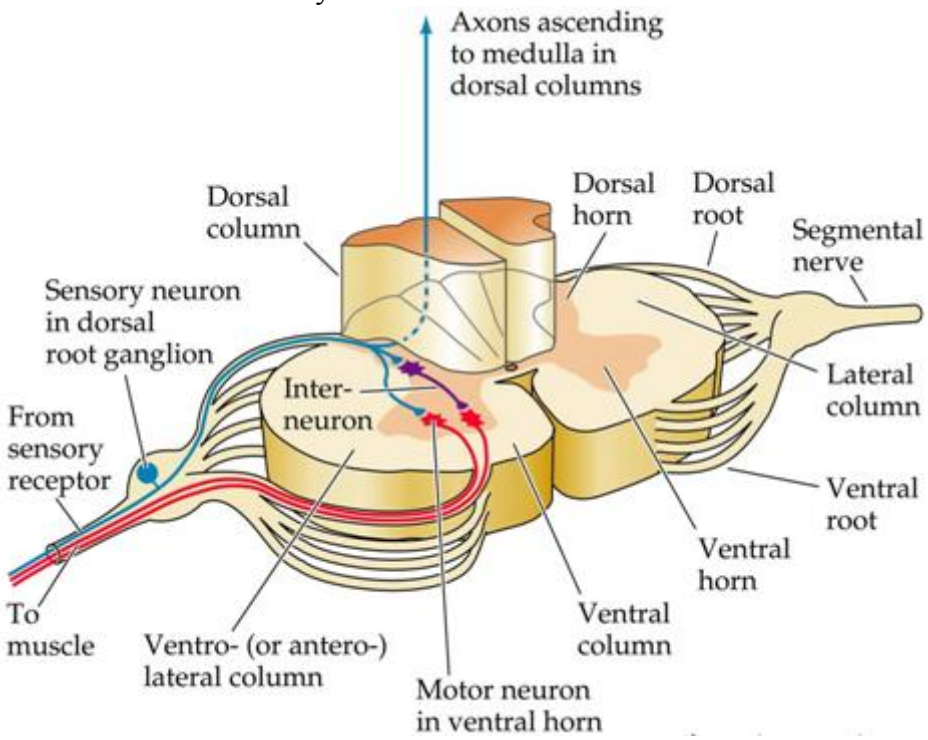


1. Meninges
    a. Dura
    b. Arachnoid
    c. Pia
2. Gray matter and spinal roots
    a. Gray is organized like a butterfly
        i. Bridge—gray commissure
    b. Gray matter columns
        i. Posterior (dorsal) horn
        ii. Anterior (ventral) horn
        iii. Lateral horn (thoracic and superior lumbar regions only)
3. Anterior horn
    a. Cell bodies of somatic motor neurons
    b. Send axons via ventral root
4. Lateral horn
    a. Cell bodies for autonomic motor neurons
        i. Sympathetic NS
    b. Leave via ventral root
5. Dorsal root ganglion
    a. Cell bodies of sensory neurons
    b. Axons project to cord via dorsal root
        i. Some enter white matter tracks and ascend
        ii. Some synapse with interneuron located in posterior horn
6. Spinal nerves
    a. Lateral fusion of ventral and dorsal roots
    b. Part of PNS (see below)

C. Spinal pathways

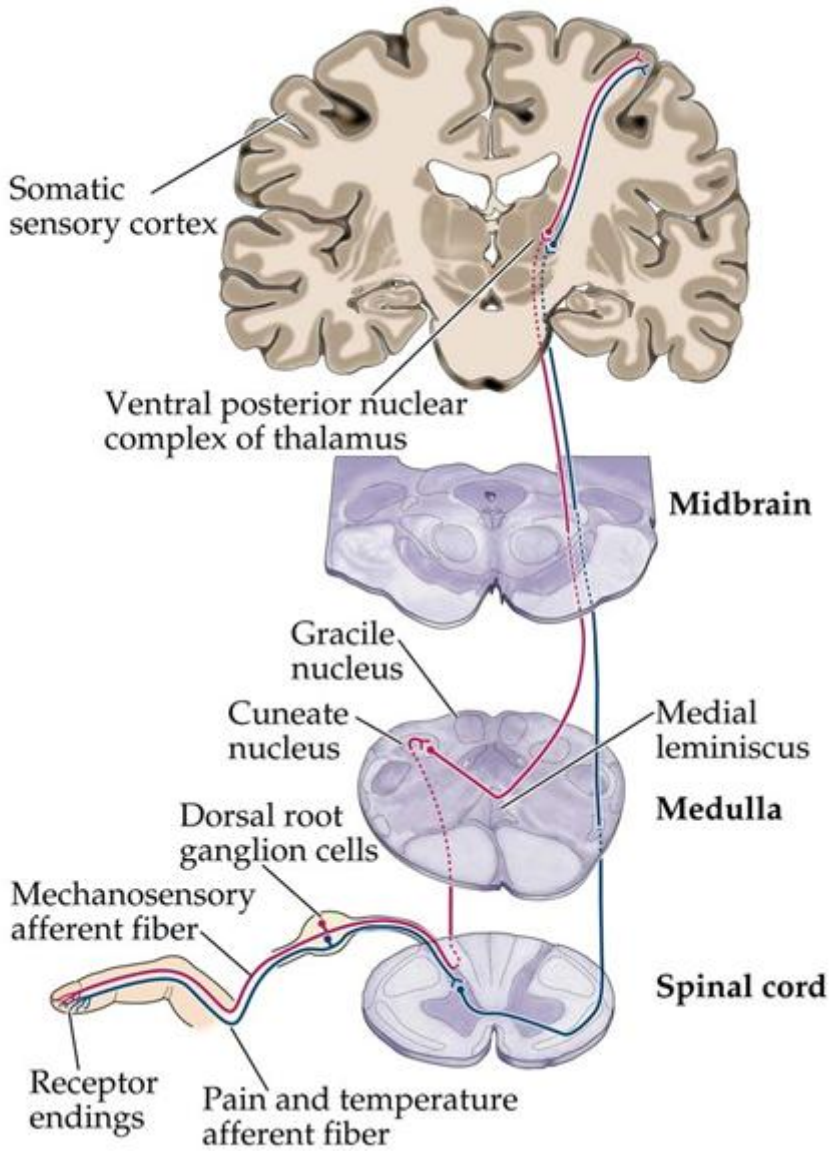


1. Characteristics
    a. Most pathways decussate
    b. Most are poly-synaptic
        i. Two or three neurons
    c. Most are mapped
        i. Position in cord reflects location on body
    d. All pathways are paired
2. Ascending (sensory) pathways (see sensory systems)
    a. Dorsal column (fasciculi cuneatus and gracilis)
        i. Touch and proprioception
    b. Spinothalamic (anterior and lateral)
        i. Pain and temperature
3. Descending (motor) pathways (see motor lecture)
    a. Upper motor neurons
        i. Cell bodies in brain
    b. Lower motor neurons
        i. Cell bodies in anterior horn of spinal cord
    c. Direct
        i. Anterior and lateral (pyramidal) corticospinal tracts
    d. Indirect (tracts)—multi-neuronal
        i. Rubrospinal
        ii. Vestibulospinal

iii. Reticulospinal
iv. Tectospinal

IX. General Organization of the Peripheral Nervous System
A. Background
1. Function
a. Connect brain with outside world
i. CNS function is dependent on information
2. Structural components
a. Sensory receptors
b. Peripheral nerves and ganglia
c. Efferent motor endings
B. Sensory receptors
1. Nature of stimulus detected
a. Mechanoreceptors
i. Touch, vibration, pressure, stretch
b. Thermoreceptors
i. Temperature changes
c. Photoreceptors
i. Light energy
ii. Exclusively in the retina
d. Chemoreceptors
i. Chemical in solution
e. Nociceptors
i. Pain
2. Location
a. Exteroceptors
i. Surface of skin
b. Interoceptors
i. Visceroceptors
ii. Visceral organs and blood vessels
c. Proprioceptors
i. Musculoskeletal organs
3. Complexity
a. Simple
i. Most sensory receptors (generalized)
b. Complex
i. Special senses (vision, audition, olfaction, gustation)
4. Generalized sensory receptors
a. Free dendritic endings (unencapsulated)
i. Free
ii. Merkel discs
iii. Root hair plexus
b. Encapsulated
i. Meisner's corpuscles—low frequency vibration)
ii. Pacinian corpuscles—high frequency
iii. Ruffini's corpuscles—deep pressure
iv. Muscle spindles—muscle stretch
v. Golgi tendon organs—tendon stretch

C. Nerves
1. Parallel bundles of peripheral axons
a. Enclosed by connective tissue
b. Some may be myelinated

2. Classification based on nature of information
    a. Sensory (afferent) nerves
        i. Sensory information from periphery to CNS
    b. Motor (efferent) nerves
        i. Motor information from CNS to periphery
    c. Mixed nerves
        i. Include sensory and motor
3. Classification based on site of origin
    a. Cranial nerves
        i. Brain origin
    b. Spinal nerves
        i. Arise from spinal cord

D. Motor endings
1. Function
    a. Activate effectors
        i. Release of neurotransmitter
2. Types
    a. Neuromuscular junction
        i. Contact between motor neuron and muscle
        ii. Release ACh
    b. Varicosities
        i. Contact between autonomic motor endings and visceral effectors and organs, smooth and cardiac muscle

E. Cranial nerves

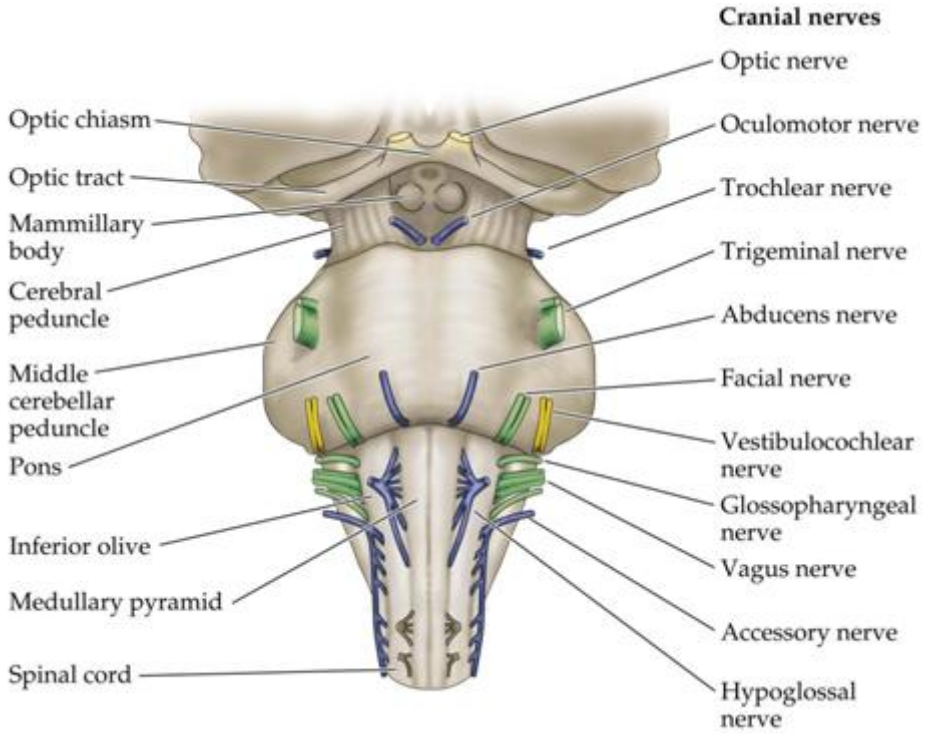


| | Cranial Nerve | Sensory Function | Motor Function |
|---|---|---|---|
| **I** | **Olfactory** | YES—smell | NO |
| **II** | **Optic** | YES—vision | NO |
| **III** | **Oculomotor** | NO | YES—eye muscles |
| **IV** | **Trochlear** | NO | YES—eye muscle |
| **V** | **Trigeminal** | YES—general sensation | YES—chewing |

| | | | |
|---|---|---|---|
| **VI** | **Abducens** | NO | YES—abducts eye |
| **VII** | **Facial** | YES—taste | YES—facial expression |
| **VIII** | **Vestibulocochlear** | YES—audition; balance | NO |
| **IX** | **Glossopharyngeal** | YES—taste | YES—tongue and pharynx |
| **X** | **Vagus** | YES—taste | YES—pharynx and larynx |
| **XI** | **Accessory** | NO | YES—head and neck movement |
| **XII** | **Hypoglossal** | NO | YES—tongue |

X. Spinal Nerves

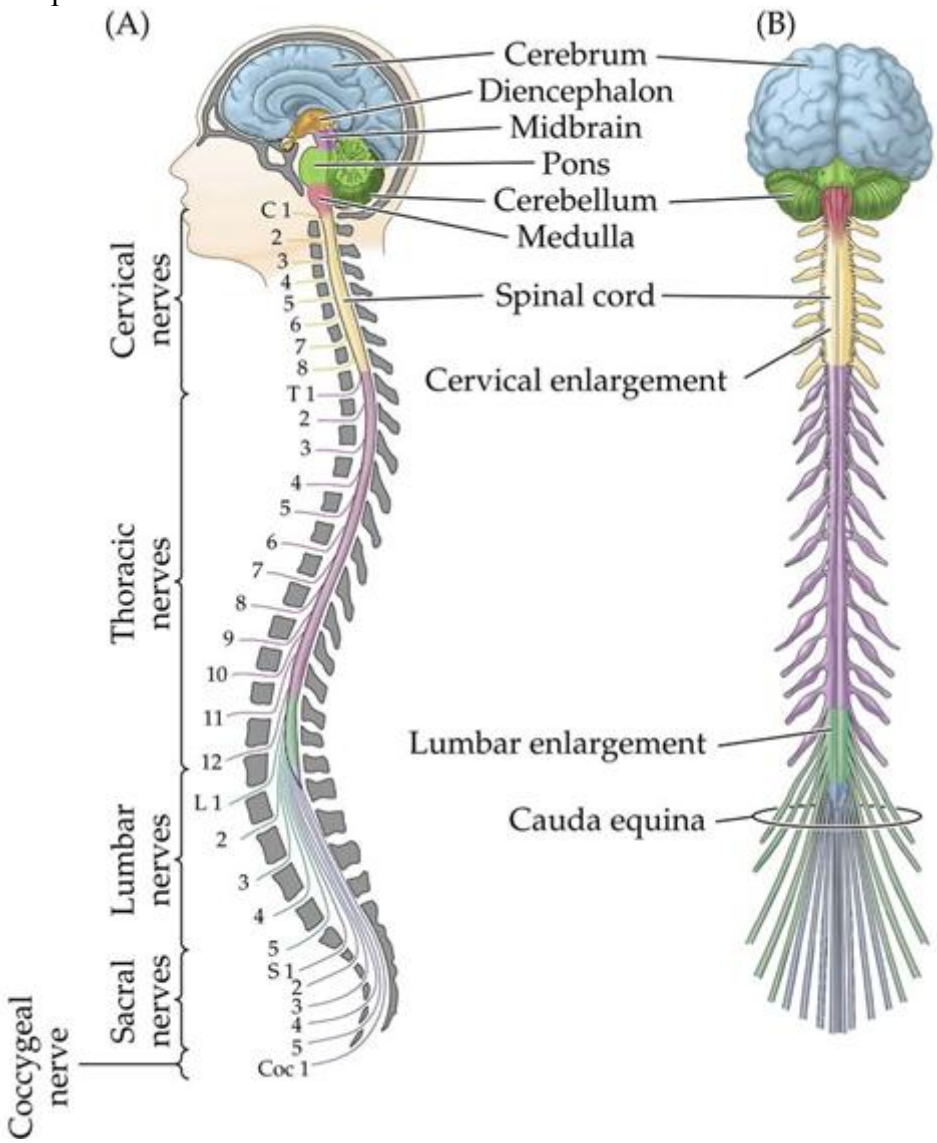


A. Nomenclature

1. Named for the level of the vertebral column from which the nerves exits
    a. 31 spinal nerves
        i. 8 cervical ($C_1 – C_8$)
        ii. 12 Thoracic ($T_1 – T_8$)
        iii. 5 Lumbar ($L_1 – L_8$)
        iv 5 Sacral ($S_1 – S_8$)
        v. 1 Coccygeal ($C_0$)

B. Structure (see above)

1. Dorsal and ventral rootlets
2. Dorsal and ventral root

3. Dorsal root ganglion
4. Spinal nerve
5. Dorsal ramus of spinal nerve
6. Ventral ramus of spinal nerve
7. Rami communicantes
    a. Autonomic fibers
8. Sympathetic chain ganglion

B. Nerves plexuses
1. Specific to ventral rami
2. Types
    a. Cervical
    b. Brachial
    c. Lumbar
    d. Sacral regions
3. Fibers of different ventral rami cross and are redistributed
    a. Branches contain fibers originating from different spinal nerves
    b. Innervation arrives via multiple routes
        i. More than a single spinal nerve serves each limb muscle

C. Dermatomes

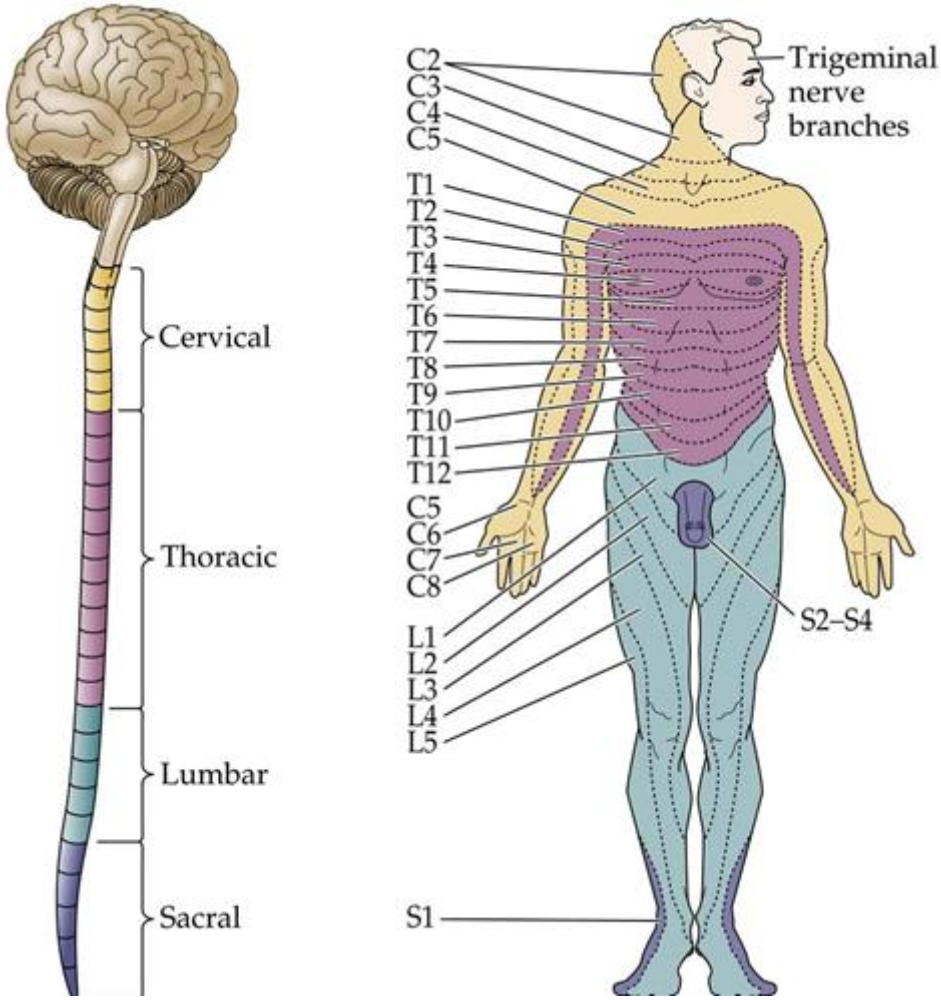


1. Area of skin innervated by the cutaneous branch of a single spinal nerve
2. All spinal nerves (except C1) have dermatomes
3. Dermatomes overlap

XI. Reflex Activity
A. Background

1. Stimulus-response sequence
    a. Unlearned
    b. Unpremeditated
    c. Involuntary
2. Mediated by spinal cord circuits
    a. Information may ultimately relayed to the brain

B. Components of a reflex arc

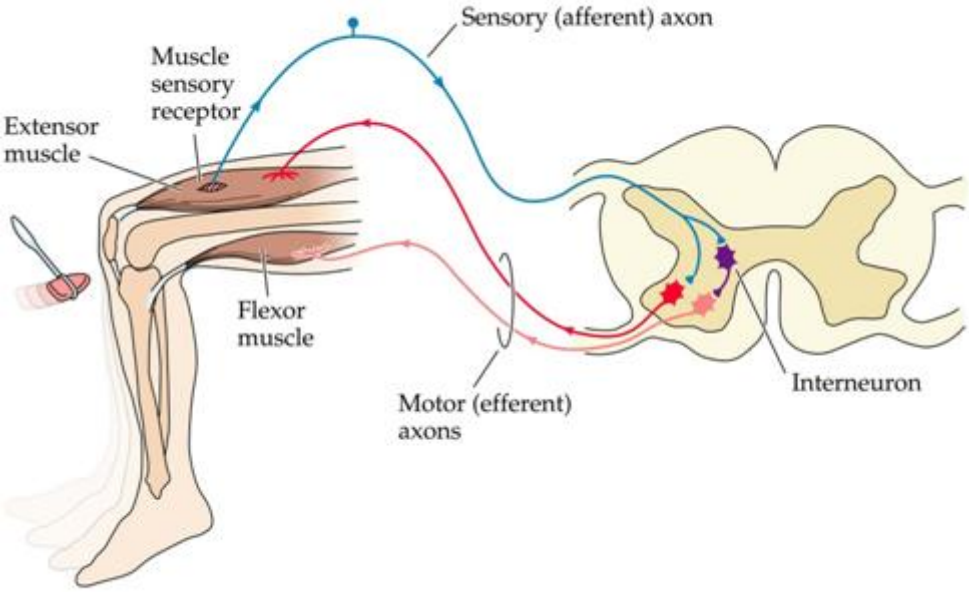


1. Receptor
    a. Site of stimulus action
2. Sensory neuron
    a. Transmits the afferent impulse to the CNS
3. Integration center
    a. Monosynaptic reflex
        i. Single synapse
    b. Polysynaptic
        i. Multiple synapses with chains of interneurons
4. Motor neuron
    a. Conducts efferent impulse from integration center to effector
5. Effector
    a. Muscle fiber or gland

C. Stretch and deep tendon reflexes

1. Muscle spindles

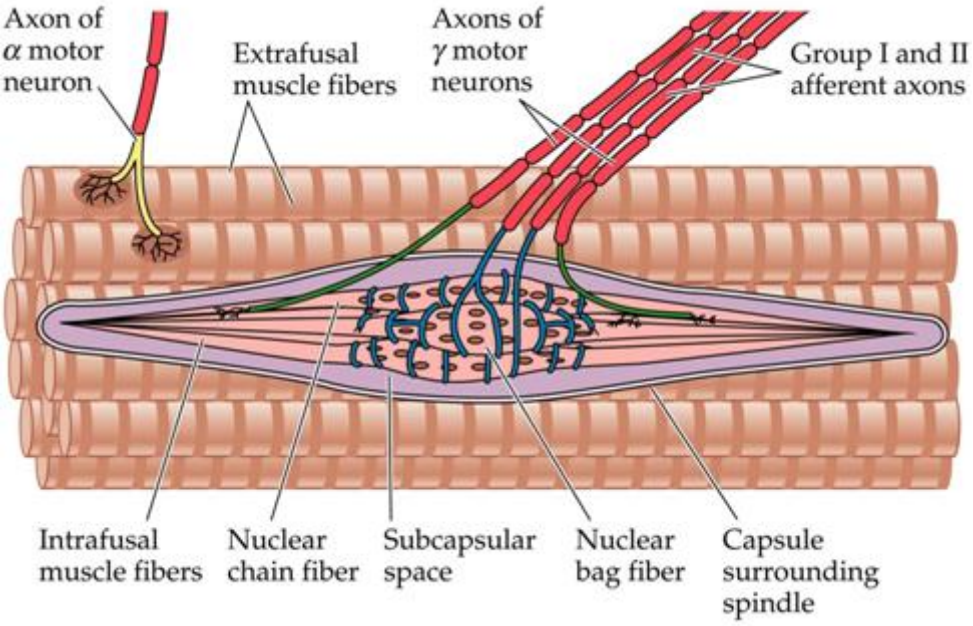


a. Consist of intrafusal fibers
b. Wrapped by afferent sensory endings
i. Type Ia fibers
ii. Type II fibers
c. Gamma (g) efferent fibers
i. Innervate contractile region of spindle
ii. Maintain spindle sensitivity

2. Extrafusal muscle fibers
a. Skeletal muscle
b. Innervated by alpha (a) motor neurons

3. Sequence of events
a. Stretching muscle activates muscle spindle
b. Impulse carried by primary sensory fiber to spinal cord
c. Activates alpha motor neuron
i. Sends efferent signal to muscle (effect)
d. Stretched muscle contracts
e. Antagonist muscle is reciprocally inhibited

XII. Overview of the Autonomic Nervous System

A. Somatic Nervous System

1. Voluntary
a. Voluntary muscle movement

2. Sensory information to the CNS

3. Organization of cell bodies
a. Lie within spinal cord or brainstem
b. Targets are controlled monosynaptically

B. Autonomic Nervous System

1. Involuntary
a. Autonomic functions are carried out without conscious, voluntary control

2. Cell bodies of all lower autonomic motor neurons lie outside the CNS
a. Autonomic ganglia
b. Neurons are postganglionic
c. Driven by preganglionic neurons whose cell bodies are in the spinal cord or brainstem

3. Divisions
a. Sympathetic

b. Parasympathetic

4. Divisions differ based on:
    a. Neurotransmitter type
    b. Fiber length
    c. Location of ganglia
    d. Function
5. Neurotransmitter

| Division | Preganglionic | Postganglionic |
|---|---|---|
| Sympathetic | ACh | NE |
| Parasympathetic | ACh | ACh |

    a. ACh acts locally
        i. ACh always has a stimulatory effect
    b. NE has spreads far and can exert its effects over long distances when circulated in the blood
    c. Adrenergic receptors
        i. Alpha—stimulatory
        ii. Beta—inhibitory (except in the heart when it is excitatory)
6. Fiber length
    a. Parasympathetic
        i. Long preganglionic
        ii. Short postganglionic
    b. Sympathetic
        i. Short preganglionic
        ii. Long postganglionic
7. Location of ganglion
    a. Parasympathetic
        i. Ganglion is located in visceral organ
    b. Sympathetic
        i. Ganglia lie close to spinal cord
        ii. Sympathetic chain ganglia
8. Function
    a. Divisions work in concert
    b. Parasympathetic dision
        i. Maintenance of function
        ii. Energy conservation
    c. Sympathetic division
        i. Emergence
        ii. Intense muscular activity
9. Sympathetic response
    a. Pupil dilated
    b. Secretory responses inhibited
    c. Stimulates sweating
    d. Heart function
        i. Increases rate
        ii. Dilates coronary vessels
    e. Increased blood pressure
        i. Constricts most vessels
    f. Bronchioles dilate
    g. Decreased activity of digestive system
    h. Piloerection
    i. Increase metabolic rate
        i. Glucose is released into blood
        ii. Lipolysis
    j. Increased alertness

h. Causes ejaculation (vaginal reverse peristalsis)

10. Parasympathetic response
    a. Pupils constrict
    b. Stimulates secretory activity
        i. Salivation
    c. Heart function
        i. Decreases rate
        ii. Constricts coronary vessels
    d. Constricts bronchioles
    e. Increases activity of digestive system
    f. Causes erection (penis and clitoris)
        i. Vasodilation

XIII. Embryonic Development

A. Background

1. Brain development begins during third gestational week
    a. Ectoderm differentiates to form the neural plate
2. Neural plate invaginates to form the neural groove
    a. Groove deepens
    b. Folds fuse to form the neural tube
        i. Occurs by the fourth week of gestation
3. Neural tube differentiates into the CNS
    a. Anterior portion forms the brain
    b. Posterior portion forms the spinal cord
4. Neural crest is formed when fold cells migrate laterally
    a. Neural crest gives rise to sensory neurons and autonomic neurons
5. Anterior develop is rapid
    a. Functional divisions are established
        i. Primary brain vesicles
6. Types of primary vesicles
    a. Prosencephalon
        i. Forebrain
    b. Mesencephalon
        i. Midbrain
    c. Rhombencephalon
        i. Hindbrain
7. Secondary vesicles form
    a. Forebrain is divided
        i. Telencephalon
        ii. Diencephalon
    b. Hindbrain divides
        i. Metencephalon
        ii. Myelencephalon

B. Brain structures associated with the developmental vesicles
    a. Telencephalon
        i. Cerebrum
    b. Diencephalon
        i. Hypothalamus
        ii. Thalamus
        iii. Epithalamus
    c. Mesencephalon
        i. Midbrain
    d. Metencephalon
        i. Pons

ii. Cerebellum

e. Myelencephalon

i. Medulla oblongata